

FIRST METATARSOPHALANGEAL JOINT ACTION

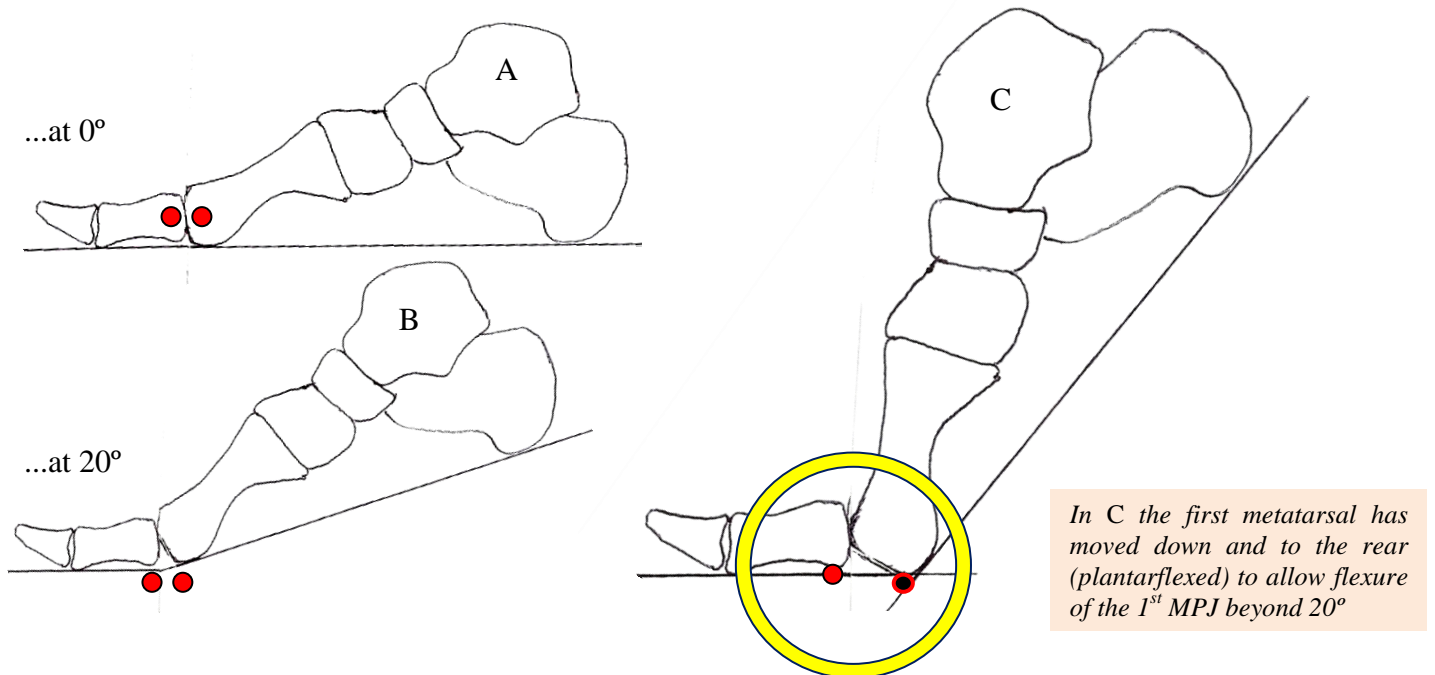
-by John Falkner-Heylings BSc (Podiatric Medicine), DipPodM, FPSPract, Podiatrist

The first metatarsophalangeal joint is ginglymoarthrodial....

gin·gly·mo·ar·thro·di·al - relating to or resembling a hinge joint and a sliding joint

When the forefoot functions in normal gait, the hallux of the normal foot is obliged to dorsiflex at the 1st MPJ. For the first 20° or so, the head of the first metatarsal pivots against the base of the proximal phalanx of the hallux, exactly as a hinge around its axis. This is *ginglymoidal* (hinge) action.

But to raise beyond that point the head of the first metatarsal must slide upon the articulating surface of the proximal phalanx... a *ginglymoarthrodial* action. The metatarsal head must plantarflex and move backwards before the metatarsal shaft can be further raised and the foot proceed towards toe-off.



FUNCTIONAL HALLUX LIMITUS

Many descriptions have been written of range of movement of the 1st MPJ. There is no absolute agreement upon the actual number of degrees that should be available, but the mode of action of the joint is well-understood....

Relative to the ground surface:

approximately the first 20° of dorsiflexion occurs around the proximal phalanx/1st metatarsal joint

- this is normal ginglymoidal motion

dorsiflexion beyond 20° requires the 1st metatarsal to plantarflex to free the hallux for further dorsiflexion

- this is ginglymoarthrodial motion

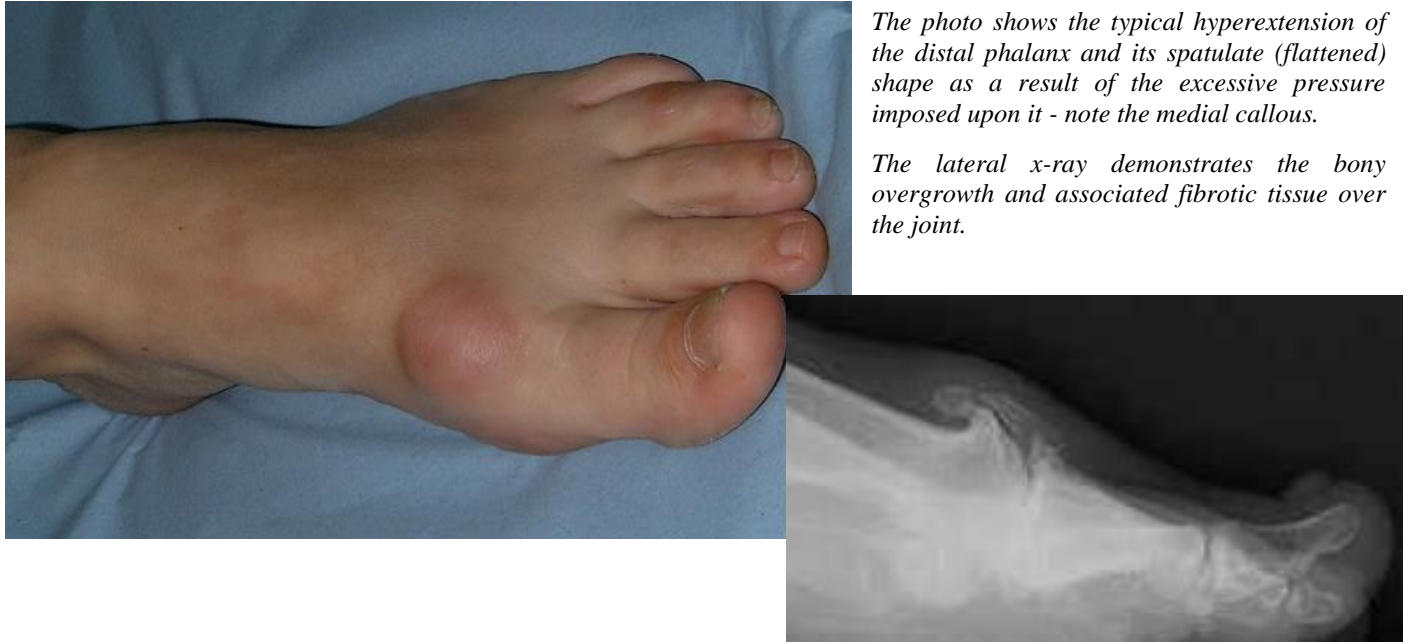In order to dorsiflex beyond 20° the first metatarsal must slide backwards and downwards, otherwise it will 'block' the further dorsiflexion of the hallux. In most feet, the first metatarsal is shorter than the second metatarsal to facilitate this action.... when the foot is about to toe-off the weight is taken last upon the heads of the lesser digits, the 1st metatarsal having plantarflexed and moved backwards to allow full unrestricted dorsiflexion of the hallux.

Failure of the 1st metatarsal to plantarflex causes impingement of the proximal phalanx upon the metatarsal, causing joint erosion and inflammatory reactions in the cartilage and bone ends. Bone irritation causes the bone to grow, and the effect of this is to restrict, and later to cause total seizure of the joint.

MEDIO-DORSAL JOINT ENLARGEMENTS

Loss of movement at the first metatarsophalangeal joint causes severe disruption of biomechanical function of foot and limb.

Medio-dorsal joint enlargements produce greater suffering than the medially positioned 'bunion' joint. These lesions are associated with **hallux limitus** or **hallux rigidus**, and the enlargement of the joint causes bony blockage of the 1st metatarsophalangeal joint.



The photo shows the typical hyperextension of the distal phalanx and its spatulate (flattened) shape as a result of the excessive pressure imposed upon it - note the medial callous.

The lateral x-ray demonstrates the bony overgrowth and associated fibrotic tissue over the joint.

At toe-off, the hallux should dorsiflex (escape upwards) as the foot is prepared to be lifted from the ground behind. If the hallux cannot dorsiflex it must transfer the entire bodyweight right out to the end of the rigid lever arm that it has become. The result is a great deal of high-magnitude stress upon the pulp of the distal hallux and the 1st MPJ. Hyperextension of the IPJ is common, as is the flattening of the distal segment of the hallux. Restriction of movement at the 1st MPJ is a recognised cause of onychocryptosis.

TO HELP THE FIRST METATARSAL TO PLANTARFLEX

To facilitate plantarflexion of the 1st metatarsal and allow unfettered dorsiflexion of the hallux we can place a 'bar' beneath the 2nd, 3rd, 4th and 5th metatarsal heads. This bar may be fashioned from dense felt or EVA, and must be deep enough to free the first metatarsal head of weight so that it can move backwards. This may prove sufficient to free a long first metatarsal. The bar can be retained in position on an insole worn in the shoe.

Alternatively, if there is already a removable insole within the shoe, that could be trimmed away from beneath the first metatarsal head and hallux, allowing them to work at a lower level.

If the foot is to be controlled by provision of biomechanical orthoses, a first metatarsal head cut-out (mild cases), or a first ray cut-out (severe cases) will promote plantarflexion of the first metatarsal. This is the idea behind Dananburg orthoses (*Howard J Dananburg – an American DPM*).

Another approach to the problem is the fitting of a 'Cluffy wedge' beneath the hallux – to pre-dorsiflex the hallux and thus allow the first metatarsal head to plantarflex by arthrodistal action earlier in gait.

If these measures do not work, then surgical intervention needs to be considered to free the joint or fix the bones of the first ray in a more favourable position so that they might be used as a 'rocker' (arthrodesis).

FIRST METATARSOPHALANGEAL JOINT ACTION

The questions on this sheet are based upon the above-named paper. Answers should be submitted on A4 paper and should be of sufficient length to demonstrate full understanding of the topic. Single word answers are not permissible. Try to answer in one or two short paragraphs, not more than a 1/4 page per answer.

Q1. Describe ginglymoarthrodial joint action. Why is it necessary?

Q2. Name the conditions that arise from faulty ginglymoarthrodial action.

Q3. Explain the action of the Cluffy wedge.

Q4. Detail two further strategies that could be employed to free the 1st MPJ.

Q5. How does a Danenberg orthosis improve first ray function?

*Return this page with the administration fee (£24 incl. VAT) and your answers to:
Alliance CPD Dept, 3 Pendoran Avenue, Colwyn Bay, LL29 8EA
A CPD credit/certificate will be issued for successful completion.*

Name:

Address:

.....

.....

Post Code: