

FIRST METATARSOPHALANGEAL JOINT FUNCTION

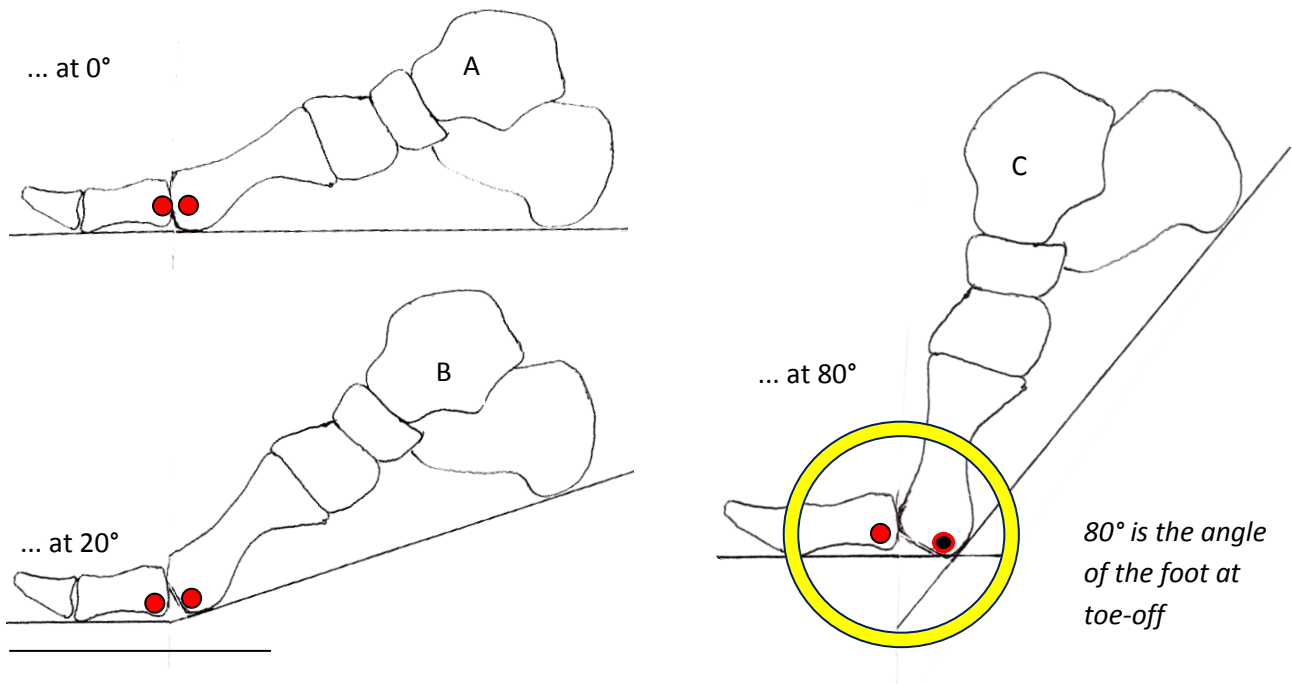
-by John Falkner-Heylings BSc (Podiatric Medicine), DipPodM, FPSPract

The action of the 1st MPJ is ginglymoarthrodial

- gin-gly-mo-ar-thro-di-al - relating to or resembling a hinge joint and a sliding joint

When the forefoot functions in gait, the hallux of the normal foot dorsiflexes at the 1st MPJ. For the first 20° or so following heel lift, the head of the first metatarsal pivots against the base of the proximal phalanx of the hallux, exactly as a hinge around its axis. This is **ginglymoid** (hinge) action.

But to raise the heel beyond that point the head of the first metatarsal must then slide upon the articulating surface of the phalanx... a **ginglymoarthrodial** action. The metatarsal head must plantarflex and move backwards before the hallux can be further dorsiflexed and the foot proceed towards toe-off.



A shows the relationship of the 1st MPJ when the foot is plantigrade.

B demonstrates the limit of simple hinge motion of the joint.

In **C** the first metatarsal has moved down and to the rear (plantarflexed) to allow extension of the hallux beyond 20°

1st MPJ FUNCTION

Many descriptions have been written of range of movement of the 1st MPJ. There is no absolute agreement upon the actual number of degrees that should be available, but the mode of action of the joint is well-understood...

Relative to the ground surface:

approximately the first 20° of dorsiflexion occurs around the proximal phalanx/1st metatarsal joint

dorsiflexion beyond 20° requires the 1st metatarsal to plantarflex to free the hallux for further dorsiflexion

In order to dorsiflex the hallux beyond 20° the first metatarsal must slide backwards and downwards, otherwise it will 'block' the further dorsiflexion of the hallux as the foot proceeds towards heel lift. In most feet, the first metatarsal is shorter than the second metatarsal to facilitate this action... when the foot is about to toe-off the weight is taken last upon the head of the second digit to allow unrestricted plantarflexion of the 1st metatarsal and toe-off from the distal phalanx of the hallux.

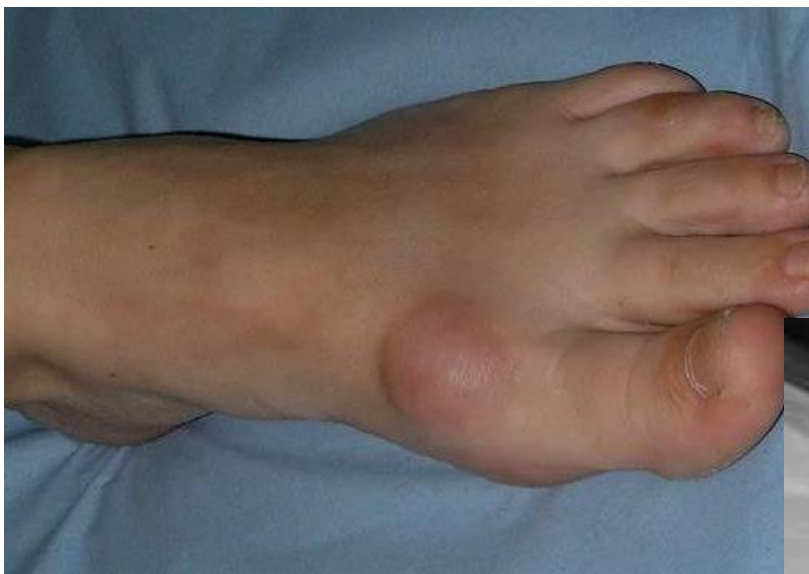Failure of the 1st metatarsal to plantarflex causes impingement of the metatarsal head on the proximal phalanx of the hallux, causing joint erosion and inflammatory reactions in the cartilage and bone ends. The trauma stimulates the bone to grow, and the effect of this osteogenic development is firstly to restrict, and later to cause total seizure of the joint. Loss of movement at the first metatarsophalangeal joint causes severe disruption of the biomechanical function of foot and limb, and compromises gait.

MEDIO-DORSAL 1st MPJ ENLARGEMENTS

Medio-dorsal 1st MPJ enlargements produce greater suffering than the medially positioned 'bunion' joint. **Hallux limitus** and **hallux rigidus** are associated with medio-dorsal joint enlargement, and the osteogenesis that occurs at the joint causes functional bony restriction of the 1st metatarsophalangeal joint.

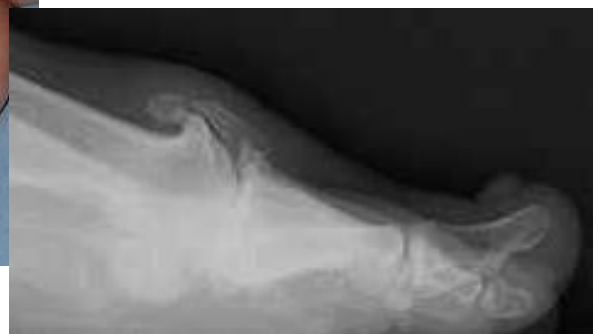Hallux limitus is the condition in which there remains some dorsiflexion of the hallux, but less than the 80° required for free ambulation. Stride length will be shortened to avoid pain at toe-off. Stress is imposed on the joint components causing inflammation of the blocked joint and fibrous and eventually bony development within the articulation.

Hallux rigidus is the condition that allows no movement whatever between the hallux and the first metatarsal. The hallux becomes fused to the first metatarsal at the 1st MPJ and the first ray becomes a rigid 'girder' or 'bar' on the medial border of the foot that has a devastating effect on foot function.



The left image shows the typical hyperextension of the distal phalanx and its spatulate (flattened) shape as a result of the excessive pressure imposed upon it since it cannot escape upwards when loaded - note the medial callous.

The lateral x-ray demonstrates the bony overgrowth and associated fibrotic tissue that prevents movement of the joint.



At toe-off, the hallux must be able to dorsiflex (escape upwards) as the heel is lifted from the ground. If the hallux cannot dorsiflex, it must transfer the entire bodyweight right out to the end of the rigid lever arm that it has become. The result is a very great deal of high-magnitude stress upon the distal phalanx and pulp of the hallux and the 1st MPJ. Hyperextension of the IPJ is commonly seen as a fixed dorsiflexion of the distal phalanx and there will be spatulate flattening of the distal segment. Restriction of movement at the 1st MPJ is a recognised cause of onychocryptosis, the 'ingrowing' toe nail. The compensation usually adopted by the sufferer of Hallux rigidus is to grossly abduct the foot and roll over it in the frontal plane so that the foot does not have to flex across the MPJs at all. This strategy inevitably leads to knee and hip pathologies.

TO HELP THE LIMITED FIRST METATARSAL TO PLANTARFLEX....

To facilitate plantarflexion of the 1st metatarsal in H. limitus and accommodate the restricted dorsiflexion of the hallux we can place a 'metatarsal bar' beneath the 2nd, 3rd, 4th and 5th metatarsal heads. This bar may be fashioned from dense felt or EVA (expanded vinyl acetate), and must be deep enough to free the first metatarsal head of weight so that it can plantarflex and move backwards. This may prove sufficient to free a long first metatarsal. The bar can be retained in position by building it into an insole worn in the shoe.

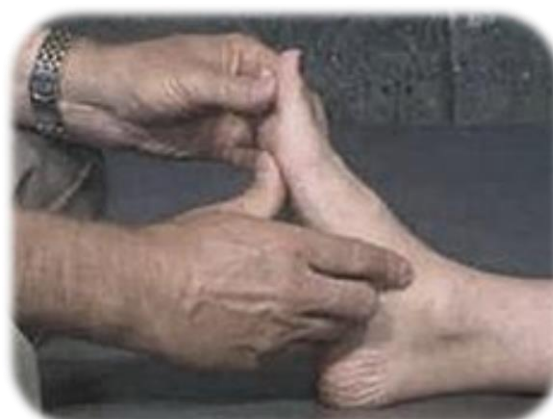Alternatively, if there is already a removable insole within the shoe, this could be trimmed away from beneath the first ray, allowing the first metatarsal head and hallux to work at a lower level.

If the foot is to be controlled by provision of biomechanical orthoses, a first metatarsal head cut-out (mild cases), or a first ray cut-out (severe cases) will allow plantarflexion of the first metatarsal beneath the level of the shell. This is the idea behind the first ray groove in Dananburg orthoses[®] (*Howard J Dananburg – an eminent American Doctor of Podiatric Medicine (DPM)*).

Another approach to the problem is the fitting of a 'Cluffy wedge'[®] beneath the hallux – the idea being to pre-dorsiflex the hallux and thus allow the first metatarsal head freedom to plantarflex earlier in gait.

If these measures do not work, then surgical intervention needs to be considered to free the joint or fix the bones of the first ray in a more favourable position (arthrodesis) so that they might be used as a 'rocker'.

Compensation to allow ambulation when the first metatarsophalangeal joint is restricted or rigid involves external rotation of the limb and excessive abduction of the forefoot. This out-turn will stretch the medial structures of the foot and induce plantar fasciitis, pronation of the foot, pressing of the tibial nail wall against the medial nail border of the hallux and closure of the joint space at the lateral side of the knee.



FIRST METATARSOPHALANGEAL JOINT ACTION

Answers should be submitted on A4 paper and should be of sufficient length to demonstrate full understanding of the topic. Single word answers are not permissible. Try to answer in one or two short paragraphs, not more than ½rd page per answer.

Q1. Describe ginglymoarthrodial joint action. Why is it necessary?

Q2. Name the conditions that arise from faulty ginglymoarthrodial action.

Q3. Explain the action of the Cluffy wedge.

Q4. Detail two further strategies that could be employed to free the 1st MPJ.

Q5. How does a Danenberg orthosis improve first ray function?

*Return this page with the administration fee (see website CPD Download page) and your answers to:
Alliance CPD Dept, Plas Erias Business Parc, Abergele Road, Colwyn Bay, Conwy, N Wales LL29 8BF*

A CPD certificate will be issued for 10 CPD points on successful completion.

Name:

Address:

.....

.....

Post Code:

Date:.....