

TOPICAL MANAGEMENT OF ONYCHOMYCOSIS

John Falkner-Heylings BSc(PodMed), FPSPract.

I have begun to question the necessity to 'treat the germinal matrix' for fungal infection. Does the germinal matrix really become infected by fungus? Ask yourself why? Why might a saprophyte invade the germinal matrix which, by definition, is alive and active? As saprophytes, dermatophytic fungi have no interest in living tissues – saprophytes derive their nutrition from the enzymatic dissolution of dead materials. In the case of dermatophytes the preference is for hair, skin and nails.

How is a fungus allowed to invade the germinal matrix? The dermal papillae of the germinal matrix are elongated to provide an extensive area of basement cells from which the onychogenic cells are produced in great numbers (Fig.1). It is the constant feeding of these cells into the nail root that causes the nail plate to grow forward. The papillae are supplied with a generous blood supply that is ensured by anastomoses of the blood vessels over the dorsal bases of the distal phalanges. The blood supply is usually only diminished by advancing age or peripheral vascular disease. By what mechanism is the fungus able to extend its hyphae within the snowstorm of new nail cells that are produced by the matrix? Why do not the white cells of the copious blood supply act to halt the progression of the slow-moving invasive hyphae? Is this really what happens and is there any histological proof that we can view to confirm that this invasion occurs? And why, if it has the ability to grow its hyphae through a dynamic region of living cell production, does fungus stop there? Why does fungus stop at the germinal matrix and not further invade the proximal tissues of the digit?

It seems more likely, given the saprophytic nature of dermatophytic fungus, that the fungus targets and invades the fully differentiated cells of the **nail root** – only after the cells have undergone onychogenic change. Only at this stage do the newly-generated nail cells meet the formula of being lifeless and having no blood supply. Only at this stage should they become attractive to any saprophyte seeking nutrition.

Why then, our obsession with getting anti-fungal agents into the germinal matrix and 'turning the blood stream into a fungicide'? If the fungus cannot invade living tissues it can only invade the historical nailplate material which only becomes so at the nail root where there is no blood supply.

Many techniques have been devised in the attempt to get the anti-fungal agent to the seat of the infection. Nailplates are reduced, thinned, ground down, flattened and even drilled to allow penetration. At the very least, the dense, dorsal keratinous layer of the nailplate must be abraded to allow absorption of the anti-fungal agent into the relatively loose and spongy mid-layer of the laminated nail plate. The middle layer of the nailplate is loose and absorbent once the dense dorsal protective layer is breached (Fig.2).

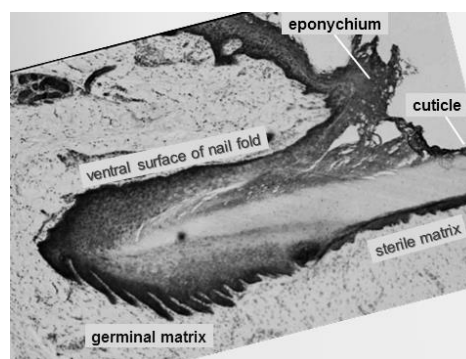


Fig.1

The nail root and germinal matrix

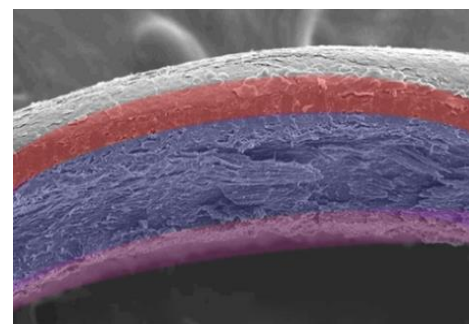


Fig.2

Layers of the nailplate (Perrin 2007).

Most of the nailplate is visible and accessible – the only part of the nailplate that remains inaccessible amounts to a strip of tissue that is shallow in depth and is rarely more than three millimetres wide. Why does it prove so difficult to bring agent and fungus together in this region? The answer is almost certainly that we do not try! Before we go down the systemic route, we should focus our efforts upon that part that the fungus has actually invaded.

There is arguably nothing new in this industry. Ideas are periodically resurrected and presented as 'new', often supported by the sale of some exorbitantly over-priced item of equipment. Drilling holes in the nailplate, as in the 'Lacuna' system, has a predecessor, the 'Nail Trephine' of Ross Fraser. Hire a well-known Podiatrist to endorse the system (not difficult) and sales can be made. Just what is the point of trying to inject fungistatic or fungicidal remedies into tissues that are going the wrong way, moving away from the germinal matrix? These 'new techniques' simply exploit the common lack of understanding of nail structure - the principle

behind them is not new, or particularly well thought out.

The simplest, shortest and most direct path to the nail root is via the thin epithelium proximal to the eponychium – this area should be the focus of our attention – this transdermal route is where our agent has the best chance of absorption and penetration,

whatever its chemistry. Established technique applied with real understanding is almost certainly the key to success.

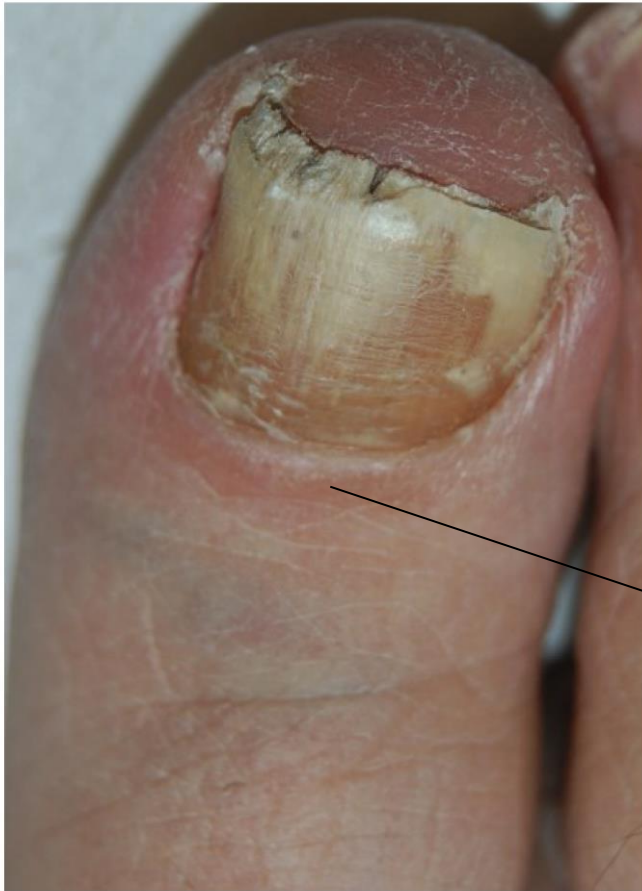

Fig3.

Note the low-grade inflammation of the tissues over the germinal matrix/nail root.

That area of inflammation indicates where we need to paint or apply our topical agent.

The area proximal to the eponychium (the dorsal nail fold) is thin and only a minimal depth of tissue overlies the nail root at this point.

TOPICAL MANAGEMENT OF ONYCHOMYCOSIS

Correct completion of this exercise will entitle you to 10 CPD credits. The answers are not necessarily given in the accompanying text and may need to be researched from text books, the Internet and scientific papers. Answers should be submitted on A4 paper and should be of sufficient length to demonstrate full understanding of the topic. Single word answers are not permissible. Try to answer in one or two short paragraphs, not more than ¼ page per answer.

1. How would you collect suitable samples for mycological investigation in a suspected case of onychomycosis? Say where the samples should be taken from and how they might be packaged for transit to the investigating laboratory.
2. Define the terms 'topical' and 'systemic'. When is a systemic treatment indicated?
3. Explain the differences between 'fungistatic' and 'fungicidal'. Name the fungistatic preparation licensed for oral administration to children.
4. Which has the highest cure rate, oral or topical therapy? In what circumstances might topical application be the treatment of choice?
5. What kind of organisms cause fungal nail and skin infection? Name those that occur most commonly.
6. How would you diagnose Tinea pedis (TP)? Include a photographic image from the Internet of TP and reference it so that it can be viewed by the reader.
7. What step is necessary to allow a topical application to enter into the nailplate?
8. How should Mykored solution be applied to toenail infections?
9. What are the merits of using Silver Sensitive cream (Laufwunder) to treat onychomycosis?
10. What measures might be recommended to a patient in order to control Tinea pedis?

*Return this page with the administration fee (£28) with your answers to:
Alliance CPD Dept, Gateway, Forest Moor Road, Knaresborough HG5 8JY
10 CPD points will be issued for satisfactory completion.*

Name:Alliance Membership No:

Address:

.....

.....

Post Code: