

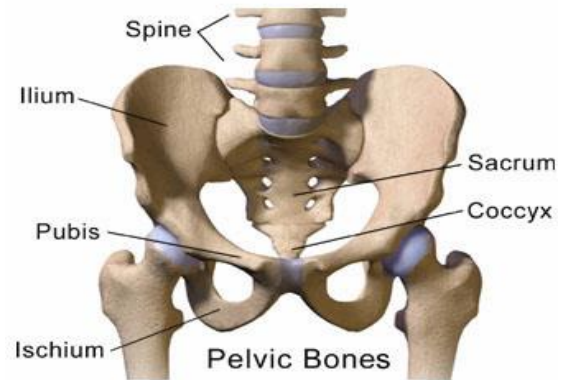
# THE PELVIS AND ITS STABILISATION

-by John Falkner-Heylings BSc (Podiatric Medicine), DipPodM, FPSPract, Podiatrist

*The pelvis is the lower appendicular girdle – appendicular because it affords appendment (attachment) to the lower limbs. The pelvis articulates with the spine above and the lower limbs beneath.*

The pelvic girdle is essentially a bony ring formed of three bones on each side – *ilium*, *ischium* and *pubis*.

In maturity, these bones fuse to create two bone masses (referred to as the *innominate* or *coxal* bones after fusion) that are attached at front and back. The back of the pelvis provides an amphiarthrotic insertion for the *sacrum* (fused mass of the sacral vertebrae) and thus supports the spinal column. The *coccyx* is continuous with the sacrum and represents the fused vestigial ‘tail’ which curls beneath and helps to form the supportive pelvic ‘floor’. Laterally, the fused coxal bones each contribute to the formation of the acetabulae that offer insertion to the femoral heads and thus give articulation to the lower limbs.



**The fusion of the bones of the pelvis, the bones of the sacrum and the bones of the coccyx are all traits of the primates - all are associated with the need of a mechanically stable mass to the adoption of upright stance. Flexibility in the lower body region is actually a hindrance to upright stance and gait.**

The pelvis supports the weight of the upper body when sitting or standing. It communicates that weight to the lower limbs in standing and walking. It importantly serves as a place of attachment for those powerful muscles that maintain upright stance and for those that mobilise the lower limbs. The pelvis acts as a stable anchorage so that muscles can insert and contract upon it without it being spatially displaced.

The *anterior junction* of the two coxal bones is known as the *symphysis pubis* – a very strong joint of fibrous cartilage overlaid with hyaline cartilage. The joint is reinforced by superior and inferior pubic ligaments.

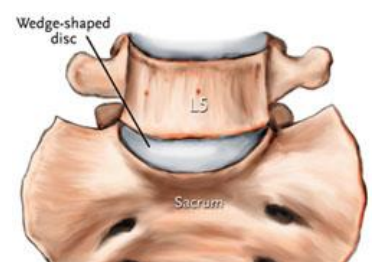
The *posterior junctions* of the pelvis are the *sacroiliac joints* – amphiarthroses allowing only very limited movement. These joints are enclosed by tight joint capsules and supported by many strong ligaments.

**The sacroiliac joints** move together as a single unit and are considered to be bicondylar joints where the two joint surfaces move correlatively together allowing flexion and extension. The stability of the sacroiliac joints is maintained by a combination of bony structure and very strong intrinsic and extrinsic ligaments. As we age the characteristics of the sacroiliac joint change. The joint surfaces are flat or planar in early life but as we learn to walk the sacroiliac joint surfaces develop distinct angular orientations and effectively ‘interlock’. They also develop an elevated ridge along the ilial surface and a depression along the sacral surface. This ridge and corresponding depression, along with the very strong ligaments, increase sacroiliac joint stability and make dislocation very rare.

**The lumbosacral joint** also allows flexion and extension (has been stated as 7° in childhood, reducing to 1° in the adult – much restricted after 35 years of age).

Spondylolysis occurs here, as do disc herniations and nerve entrapments.

Ligaments of the pelvis strengthen and reinforce the bony structure and help smooth the inner surfaces that support the viscera. The inguinal ligaments help to extend and make the bowl shape more complete. Other ligaments help form the floor of the pelvis and yet others produce a ‘button-hole’ effect by winding around the femoral heads and pulling them into the acetabulae.



# ALLIANCE PROFESSIONAL DEVELOPMENT

## THE PELVIS AND ITS STABILISATION

*Your responses should be submitted on A4 paper and should be of sufficient length to demonstrate your understanding of the topic. Each answer requires a short essay (typically 500 words or 1/2 page A4).*

Task 1

Describe the pelvis and its anatomical relationships.

Task 2

Explain why there are so many bony fusions in the pelvic region.

Task 3

Which bones form the acetabulae?

Task 4

Describe the various roles of ligaments in the pelvic region.

Task 5

Why does the lower limb require 'stable anchorage' to be able to function?

*Please sign the following declaration and submit it with your response:*

*"I certify that the work that I have submitted is my own original work, and that any previous work that I have drawn upon has been given due credit by showing reference to that work"*

Signature: .....

*Return this page with the administration fee (see website CPD Download page) and your answers to:*

*Alliance CPD Dept, Gateway, Forest Moor Road, Knaresborough, North Yorkshire HG5 8JY*

*A CPD certificate will be issued for 10 CPD points on successful completion.*

---

Name: .....

Address: .....

.....

.....

Post Code: .....

Date:.....