

# CLINICAL MANAGEMENT OF THE INGROWING TOE NAIL

- by John Falkner-Heylings BSc, DipPodM, FPSPract

*This technical paper refers to the condition and treatment of onychocryptosis, in which the nail plate has broken through the epidermis and occupies the entry wound.*

## THE RELATIONSHIP OF RELEVANT NAIL STRUCTURES

The **nail plate** arises from the **nail fold**, an invagination of the epidermis on the dorsal surface of the distal extremities. The **eponychium** seals the distal edge of the nail fold against ingress of fluids and dirt.

The visible **nail body** resides upon the **sterile matrix** and migrates forward with it, advancing distally as cells are generated by the **germinal matrix** beneath the hidden **nail root**. The borders of the nail plate occupy medial and lateral **nail sulci** and are defended by **nail walls**, epidermal folds that arise from the sulci.

The **hyponychium** is that part of the epidermis from the point at which the nail body separates from the sterile matrix to the point at which the tissue beneath the nail body becomes normal epidermis at the **yellow line**. The leading edge of the nail plate that overlies the hyponychium is known as the **free edge**.

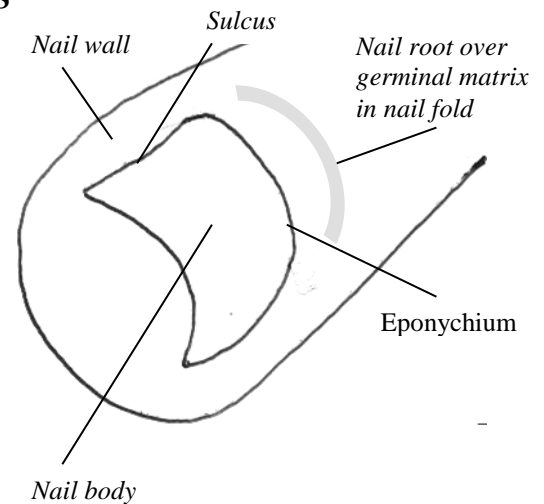


Fig.1

## AETIOLOGY OF ONYCHOCRYPTOSIS

Onychocryptosis can arise as a result of faulty trimming, or from direct trauma, HAV, excessive foot abduction, or metatarsus primus adductus. Involuting nails seem to predispose to the condition but improper trimming is probably the real factor here. It occurs most often in the second and third decades of life and is common in the sports-orientated. The nail plate penetrates through the skin creating a wound and holding open a portal for infection. The infective organisms may actually be introduced to the wound by the nail plate on first entry.

## AIMS OF TREATMENT

The primary aim is to close the wound and control infection. The intrusive portion of the nail must be removed from the wound so that closure can be achieved and infection controlled.

## TREATMENT OPTIONS AND INDICATORS

Treatment delivery depends upon the causation of the condition and the severity at presentation. The halluces are most often implicated due to the magnitude of forces that act upon them, although any nail has the potential to 'ingrow'. There will nearly always be pain, redness and swelling, and the wound may exude serum, or blood. Where onychocryptosis has been allowed to develop without intervention the condition is often complicated by the formation of hypergranulation tissue. Hypergranulation tissue is formed when a wound cannot close (here because of the presence of the intrusive nail portion). The physiological strategy adopted is to produce masses of vascular, poorly differentiated (unfinished and unstratified - disorganised) cells with great rapidity, with the intention of defending the body against pathogenic invasion by smothering the wound - much as fire-fighters spray copious amounts of foam upon a fire to exclude the air. Hypergranulation tissue will not form where there is no cause, and will rapidly disappear when the irritant nail is removed to allow wound closure. These tissue masses can obscure our view of the wound and complicate our approach. The tissue can be rapidly reduced by application of a silver nitrate 95% caustic pencil or by application of a cryogen. The wound (and the

hypergranulation tissue) may exude serum or blood which will dry and crust around the site, adding to the adverse appearance of the lesion. Hypergranulation tissue has no organised nerve supply, nor does it have an organised network of nerves, so pain and bleeding will be minimal. Lesions where the layers of tissue are still dry and closely bonded are the most difficult to address. Wounds of longer standing that are wet, macerated and infected are actually easier to work upon as the structures separate in the fluid and dissect more readily.

Local anaesthesia is needed for the most severe cases where permanent curtailment of growth is seen to be necessary. There are risks (anaphylactic shock) with all anaesthetic procedures, and anaesthetic procedures should not be undertaken by any practitioner not fully conversant with basic life-saving skills and suitably supported by trained staff and resuscitation equipment. The effects of procedures completed under anaesthesia are not appreciated by the patient until the anaesthetic fades, and there is potential for damage to the operation site whilst the anaesthetic persists (approx four hours following administration).

Many cases do not need local anaesthesia. Careful explanation of the intended procedure and what the patient will experience will usually lead to patient understanding, consent, acceptance and compliance. If lesions can be operated upon without anaesthesia the procedure can be rapidly performed with few complications. The relief resulting from successful removal of the offending nail portion can be immediately appreciated by the patient, and is often accompanied by euphoria.

## REMOVAL OF THE OFFENDING NAIL SECTOR WITHOUT LOCAL ANAESTHESIA

Removal of the penetrating nail portion is essential to closing of the wound. Closing the wound allows control of infection. Priority must be given to removing the intrusive nail segment. Antibiotics or antiseptic preparations will allow effective infection control only when the wound is closed. Trying to control the infection by antibiotics whilst not addressing the necessary removal of the nail spur must inevitably repeatedly fail, since the wound is being held open and irritated by the presence of the nail. The procedure that must be undertaken to remove the penetrating nail portion is that of *Wedge Section*.

**Instruments:** the following instruments must be assembled for the procedure:

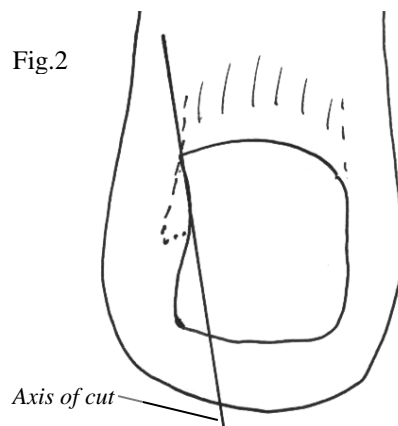
ingrowing nail nippers (not Thwaites nail splitters), swan-necked excavator with sharpened bowl, Black's file, cotton wool, packing instrument, small spatula, a dry-powder antiseptic spray (Betadine or AlphaSilver), non-adherent dressing, 01-12 tubular gauze, Haplaband strips 1.25cm x 7.5cm.

**Preparation:** the toe to be operated upon and the entire forefoot should be prepared by spray application to all surfaces of a suitable pre op such as Chlorhexidine gluconate 0.5% in 70% IMS (CX1). If the ingrown nail is long it should be reduced to a reasonable length using multiple small cuts with the tips of sharp nippers, taking care to minimise the break-through shock. This is necessary to prevent undue post operative sagittal plane mechanical stress upon the nail plate.

**Procedure:** The patient is often well aware of the exact location of the problem and can give useful initial guidance. Gentle palpation of the nail wall may reveal the position and extent of the intrusive nail portion.

Take up the ingrowing nail nippers and apply them to the nail, taking care to steer the lower jaw of the nipper around and beneath the lateral border of the nail plate. Do not create a stab wound by thrusting the sharp tips, but rather slide or roll the nippers into position, taking care to tilt the sharp end of the lower jaw up towards the underside of the nail plate. The jaws can be then be held slightly apart and rotated towards toe mid-line, forming a mechanical couple to raise the nail plate border from the sulcus and bring it into full view. Following examination of the nail edge the rotation can be relaxed somewhat, but the nail edge must not

Fig.2



*Line of cut designed to remove spur and exit at side of nail plate below the discontinuity. Note how the cut edge of the remaining nail plate is angled to act as a 'snow plough' and push the soft tissue aside as the nail body advances.*

be allowed to return fully to the wound from which it came. The nipper jaws must remain in position and can be advanced at this point, if necessary. The angle of the wedge is determined, and only now can the jaws be closed together to separate the wedge section. The outcome of closure of the jaws must result in the proximal end of the cut being off the side of the nail, below the discontinuity (see Fig.2). The proximal end of the cut being thus determined, the angle of the cut is planned so as to leave the remaining nail plate as wide as possible at the distal end for pulp control. The nippers must be closed firmly, and the effectiveness of the separation should be detectable to the operator. The greatest mistake that can be made at this point is not to see the procedure through thoroughly. Having begun the cut it must be continued to the lateral nail border, however far beneath the eponychium it is necessary to go to achieve this. It must, however, exit by the lateral border, not the proximal germinal border. It may be necessary to roll with the curvature of the nail to produce a straight cut. Having performed the section the portion to be removed is grasped in the jaws of Halstead or Steadman forceps. These instruments have short (and therefore stiff) serrated jaws for a positive grip on the fragment. By turning towards the midline of toe the nail segment can be freed from its attachments and withdrawn. The procedure, performed skilfully and quickly, will not prove unduly painful and the relief of the spur removed justifies any transient discomfort. The swan-necked excavator or Black's file is employed to ensure that there is a smooth and continuous straight edge left on the lateral nail plate border after removal of the splinter, and to remove any discontinuity that may be found.

### **WOUND CLEANSING AND POST OPERATIVE DRESSING**

If the lesion is seen by the presence of pus to be infected, it is appropriate to debride the wound using hydrogen peroxide 3% soln.\* This preparation is antiseptic in its own right. Breaking down as it does in the presence of blood or pus, it produces harmless water whilst liberating oxygen. The oxygen bubbles physically scour the walls of the cavity, lifting infection debris from the tissues so that it can be washed away. **Important-** *note that the cavity must then be copiously and freely irrigated with isopropyl alcohol to wash away all traces of hydrogen peroxide and leave the wound as clean as it can be made. Note that 3% soln Hydrogen peroxide will do little damage to the surface tissues of the cavity, certainly no more than the infection toxins would have caused if allowed to remain. Note also that the cavity is open and not closed. Thorough washing of the wound with isopropyl alcohol ensures that there is no risk of oxygen embolism. \*(This goes against the current teaching of NHS wound healing advisors, but we are not, in this instance, trying to heal recalcitrant ulcers in immunocompromised patients).*

The wound may then be treated with an antiseptic to kill any residual pathogens and prevent further infection. Povidine-iodine dry powder spray (Betadine®) is ideal for this, as drop of Ispropyl alcohol will carry it down into the depths of the wound and the seat of any infection. There will be a transitory alcohol-induced 'sting' at this point. (The application of Friar's Balsam or Compound Tincture of Benzoin is contraindicated in this instance - these compounds are medical varnishes that might seal infective organisms in and prevent free drainage). Application of a sterile non-adherent, low bulk dressing (e.g. Melolite®), retained with tape and covered by an overdressing of tubular gauze will keep the wound clean and provide primary protection. Secondary protection must be provided by footwear that must on no account apply pressure to the operation site.

### **POST OPERATIVE MANAGEMENT**

Keeping the wound dry for the first 24-48 hours (depending upon the severity of the wound) will allow the wound to close. First follow-up should be between 48 and 72 hours after the procedure, with further review and re-dressing as necessary. Normal hygiene can be resumed when all exudation has ceased.

### **FUTURE MANAGEMENT**

The nail plate will in most cases grow out uneventfully and establish a full width plate. There will be no scarring and there is no permanent mutilation or loss of the nail's protective function. Education in correct nail trimming must be given to prevent recurrence.

Cases that do not resolve following this procedure must be referred to a Podiatrist or General Practitioner for PNA-partial nail ablation or TNA-total nail ablation under local anaesthesia.

## CLINICAL MANAGEMENT OF THE INGROWING TOE NAIL

*Answers should be submitted on A4 paper and should be of sufficient length to demonstrate full understanding of the topic. Single word answers are not permissible. Try to answer in one or two short paragraphs, not more than a ¼ page per answer.*

- Q1. Describe the anatomical relationships of the nail plate.
- Q2. Name five conditions that can give rise to onychocryptosis.
- Q3. What is the primary aim of treatment in onychocryptosis.
- Q4. What is hypergranulation tissue?
- Q5. How could hypergranulation tissue be rapidly reduced?
- Q6. What is the risk attached to local anaesthesia?
- Q7. How is infection best controlled in onychocryptosis?
- Q8. How is the angle of the wedge section determined?
- Q9. Why are medical varnishes contraindicated in post-operative dressings?
- Q10. Detail the post operative management of onychocryptosis patients.

***Return this page with the administration fee (see Alliance webpage) and your answers to:  
Alliance CPD Dept, Gateway, Forest Moor Road, Knaresborough HG5 8JY  
10 CPD points will be awarded for successful completion.***

Failure to gain 40 CPD points in a practice year will leave you eligible for audit.

---

Name: ..... Alliance Membership No:.....

Address: .....

.....

.....

Post Code: .....

---