

TOE NAILS - FUNCTION AND MANAGEMENT

- by John Falkner-Heylings BSc, DipPodM, FPSPract

We regularly hear that trimming toe nails is 'not rocket science'. This remark is invariably made by individuals with limited experience or restricted observational powers allowing them to overlook the effects of poor trimming. Rocket science it may not be, but there is a great deal of other science that should properly be applied to the trimming of toe nails.

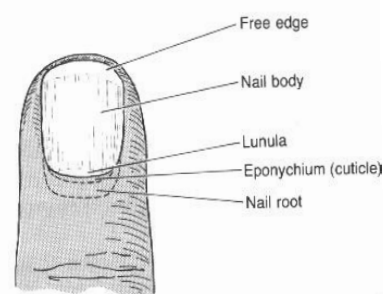
The nail is a phylogenetic remnant of the mammalian claw and consists of a plate of hardened and densely packed keratin.¹

Nails are a protective cover for the ends of the fingers and toes which also help increase tactile sensitivity by exerting counterpressure over the distal pulp.²

THE ANATOMY OF THE NAIL:

The **nail plate** occupies and grows from an invagination in the epidermis over the dorsal aspect of the distal segment of a digit (the **nail fold**). The nail plate consists of a **nail root** (the part that remains in the nail fold), **nail body** (the visible part) and its **free edge** (the part that may project beyond the distal attachment of the nail plate). The point at which the free edge becomes free and the area that lies beneath the free edge is the **hyponychium**. This is bounded distally by the **yellow line** (not particularly yellow, but the line at which the nail structures give way to normal epidermal skin). The **eponychium** (known popularly as the cuticle) is the narrow band of epidermis that attaches proximal nail fold to nail plate to seal against ingress of fluids and foreign bodies.

The nail root arises from the **germinal matrix** which is usually attached to the periosteum of the distal phalanx and it is this attachment that anchors the nail plate firmly in position. The **lunula** is a pale crescent-shaped extension of the germinal matrix which can be seen through the nail plate. The nail plate otherwise lies upon the **sterile matrix** and is bounded laterally by the **nail walls**, epidermal folds that protect the lateral nail plate borders. The nail walls arise from the nail fold and **nail sulci**. These sulci (nail grooves, gutters) are continuous with the sterile matrix and nail walls.



PHYSIOLOGY OF THE NAIL:

Growth of the nail occurs by the transformation of superficial cells of the matrix into nail cells. In the process, the outer, harder layer is pushed forward over the stratum germinativum.³ Most of the onychogenic activity occurs in the germinal matrix, whilst the sterile matrix migrates with the nail plate as it advances distally but adds little substance to the mass of the nail. It has been stated that growth of finger nails is about 1mm per week, the growth rate of toe nails being three to five times slower. It is said that growth rate is related to length of digit, being faster on the longer digits. Growth is fastest in youth, slowing with advanced age, vascular disease or ill health. Growth is affected in a health crisis, and this might be demonstrated by a transverse Beau's Line (growth arrest line) or onychomadesis where the nail plate continues to move distally and is shed when it loses its adhesion to underlying tissues.⁴

The germinal matrix cells lie beneath the nail root in an arc dorsal to the distal phalanx and distal to the last interphalangeal joint. This arc may be visualised as a 'duct' producing a 'profile' of nail. If the duct is blocked, distorted or damaged the profile will be altered in cross-section, thickness or continuity. The germinal matrix may be subjected to mechanical trauma and this may result in permanent damage. Repetitive microtrauma is often sufficient to cause permanent damage. The germinal matrix is highly vascular, being supplied by a multiplex of arterial anastomoses. Nail production reduces as the blood flow is reduced. The structure is also subject to bacterial, fungal and yeast infection. Recovery from these infections depends largely upon the extent and duration of the infection.

NAIL FUNCTION AND PURPOSE:

Nails assist with investigation of the world around us. They also enhance dexterity in grasping and manipulation of small objects. They protect against damage to the digit ends, whilst assisting in oral maintenance, grooming and scratching. There is also an important role in offence and defence. Proprioception is gained from pressure of the pulp against the hard underside of the semi-rigid nail plate. The nail plates give form and shape to the pulp of the digit and, by attachment to the distal phalanx control and stabilise the pulp. On the foot, the toe nail is most importantly functional in its proprioceptive role, its defence of the digit and in control of the toe pulp.

EFFECT OF GROUND FORCES UPON THE NAIL AND RELATED STRUCTURES:

Static When a toe pulp is loaded in standing, the pulp of the toe will transmit pressure to the underside of the nail plate. This feeds back proprioceptive information to the brain upon attitude of stance in order to maintain balance and stand erect. The correctly trimmed nail will resist that pressure and control the position of the pulp. If the nail were to be trimmed too short the pulp and sulci would rise vertically upwards in front of the distal cut edge and medial and lateral corners of the nail, presenting an ill-defined soft tissue mound through which the nail plate will inexorably attempt to advance.

Motive When the foot functions normally in gait with propulsive toes the distal end of the digits will be rolled against the ground so as to sequentially load the toe pulp. Pressure will normally be transmitted through the pulp to the underside of the nail plate. As toe off approaches the pulp pressure will lastly be distally applied beneath the hyponychium and nail free edge. If the free edge is positioned correctly, the compressive pressure upon the pulp will fall away as the load finally transfers to the apical aspect and toe off occurs. But, if the free edge is cut too far back there will be no control of the pulp at this late stage. The pulp will be expressed vertically beyond the plane in which the nail would have exerted control, thus effectively rising up in front of the nail plate. Now, at the distal end of the nail plate are the medial and lateral corners of the nail plate lying within the nail sulci. Gait dynamics force the uncontrolled, too-flexible pulp and sulci onto the short nail plate edge and corners, which must take the pulp pressure. This pressure is sometimes the origin of the onychocryptotic nail. Note that the pulp and sulci are pressed onto the nail edge and corners, not the innocent nail through the pulp.

GENERAL PRINCIPLES OF NAIL SHAPING

The practitioner needs a mental model of the 'ideal' anatomy to compare and contrast with that which is presented. There must also be an understanding of the normal function of the nail and the dynamics of that function. Interaction with adjacent digits must also be taken into consideration. The aim is to produce the closest possible approximation to the ideal from any given pathology. Nippers, excavators, files and practice motors are required to be used with considerable exercise of control, skill and dexterity. The intention must be to achieve the optimal extent, coverage, shape and flexibility in any given situation with constant reference to the dynamics of the soft tissue surrounding structures, including allowance for expected growth.

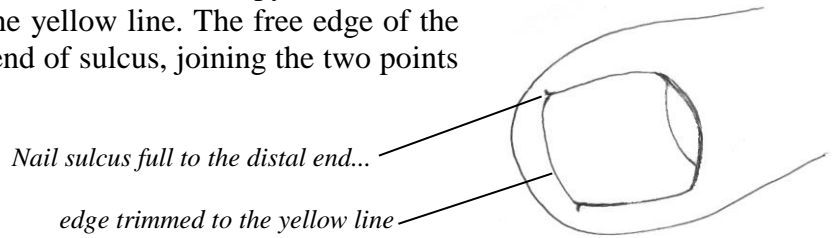
Work upon the nail plate and surrounding structures must take into account the great sensitivity of the anatomy in the region. The greatest risk is of heat generation when using burs. Concentricity of burs is essential. Practice motor handpieces with high quality bearings to minimise run-out (wobble) turning at higher rotation speeds (circum 12-30,000rpm) produce least vibration. Well maintained sharp burs with appropriate particle size applied with light pressure generate least heat, and intermittent application of the bur prevents heat build-up and allows dissipation of heat whilst working. Eyes must be protected from the larger displaced particles and pulmonary inhalation of dust must be controlled for safety of the operator and patient. Wet drills offer superior dust control and the compressor-propelled water acts as a coolant allowing expansion of technique.

TRIMMING THE NORMAL NAIL

The trimmed nail should cover the entire sterile matrix, occupy both sulci to their distal ends, and extend forward to the yellow line. The free edge of the nail should extend from end of sulcus to end of sulcus, joining the two points by an aesthetic curve.

The distal ends of the sulci must not be exposed. In foot health practice the free edge is generally removed entirely.

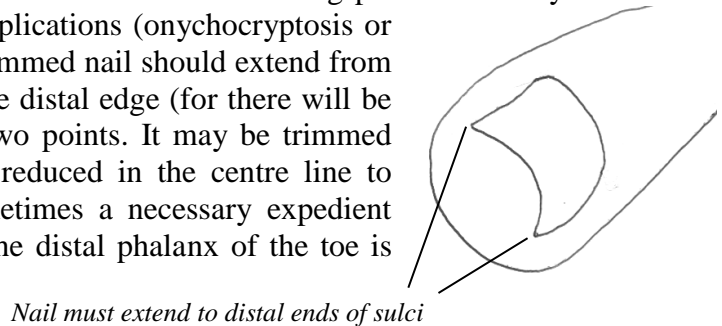
Growth from this point to next requirement of trimming takes, on average, 6 weeks for those in their 60s, 7 weeks for those in their 70s, and 8 weeks for those in the eighth decade of life.



TRIMMING THE INVOLUTED NAIL

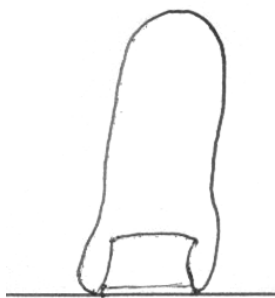
Involuted nails enclose a variable volume of toe pulp. This enclosed toe pulp may become keratinised at the apex, so much so that the hyperkeratosis may blend and appear to fuse with the nail, effectively forming a 'box' which makes the application of nippers difficult. However, the 'box' can be opened, if necessary using ingrowing nail nippers or a cut-steel bur, and the hyperkeratosis reduced. The profile of the nail plate can then be seen, and is usually observed to be no thicker than a normal nail plate. The nail can then be reduced in length to level with the soft tissue surface - never below. Every effort should be made to retain the corners intact. The nail grooves must remain filled to their distal extremities by nail.

The sides of an involuted nail are best left alone, if comfortable. Cleaning of the nail sulci and any other interference should be minimal. Trimming down the sides and inserting packs is usually not necessary and is not recommended unless there are complications (onychocryptosis or onychophytic corns in the nail groove). The trimmed nail should extend from distal end of sulcus to distal end of sulcus. The distal edge (for there will be no free edge) can be shaped between these two points. It may be trimmed either to be straight across or may even be reduced in the centre line to produce a negative curve. This latter is sometimes a necessary expedient where the involution is very steep or where the distal phalanx of the toe is upturned or retracted.



TRIMMING THE NAIL OF A RETRACTED DIGIT

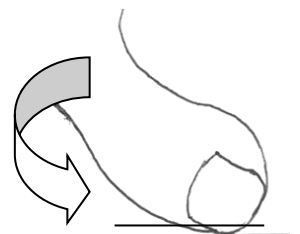
Where lesser digits are grossly retracted, ground forces are applied (from the innersole of the shoe) directly to the apices of the toes. This means that the free edge of the nail is subjected to ground force and the nail plate is forced longitudinally back into the matrix. This is often the origin of the thickening (hyperkeratosis) of the nail plate since the matrix produces more nail substance as a result of the extra blood flow occasioned by both the stimulus and the subsequent inflammation. The free edge of the nail plate must be cut back or made minimal to reduce the amount of ground force received. So far as is possible, the cut edge should be made parallel to the ground/innersole surface. The aim should be to remove the nail from the ground effect, or minimise ground contact.



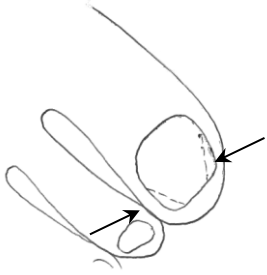
TRIMMING THE NAIL OF AN AXIALLY ROTATED DIGIT

Sometimes a lesser toe is twisted, usually medially by a rotational force. This in turn causes the same rotational force upon the nail plate which will respond by growing in a curved manner, the side touching the ground growing the fastest.

Here the lateral corner of the nail will need to be trimmed parallel to the ground surface in order to relieve it as much as possible from the ground force.



HALLUX ABDUCTOVALGUS



In the case of hallux abductovalgus, the hallux nail receives ground force or shoe contact force upon the medial corner of the nail plate. This presses the medial soft tissues onto the medial corner of the nail plate, compromising the local blood supply and causing onycholysis (breakdown of the bond between nail plate and nail bed), or onychocryptosis (ingrowing toe nail). The hallux, being pushed laterally, is pressed against the second toe - pressurising the lateral sulcus and pulp. Again, onycholysis or onychocryptosis may be the outcome. Here the nail of the second toe must be carefully managed to defend the lateral soft tissue of the hallux. HAV most often occurs as a concomitant to hyperpronation of the foot. This leads to retraction of the lesser toes and loading of the apices.

SUMMARY

If nails are reduced properly by appropriate use of nippers and the process finalised by smoothing with a dresser, file, bur or stone, there should be very little need to intrude beneath and around the structures with Black's files and excavators. To do so is to disturb that which is often quite comfortable and break natural seals which are resistant to infection. Correct nail extent after trimming is seen to be vital to the stabilisation and control of the toe pulp and soft tissues of the digit. Loss of nail plate - particularly at the distal corners - leaves the pulp uncontrolled and vulnerable to whatever forces are applied.

From the above it can be seen that there can be no single nail cutting technique applicable to all nails. Each case, indeed each digit, must be assessed and treated according to the need. Nail trimming will range from normal cutting where there is no threat to the digit, to shaping and easing of the nail plate in response to the assessed threat. In addition to the application of the principles stated above, there is often a requirement to reduce the thickness of a nail plate. Doing so reduces the mass of the pathological nail plate pressed into the dorsal aspect of the toe, delivering comfort, preventing further and deeper pathology and allowing more room for movement in the toe-box of the shoe. The nail will then not be pressed so tightly upon the digit and thus will cause no advance in the pathology.

REFERENCES:

1. Gawkrödger DJ, *Dermatology* 3rd ed. p4, 2003: Edinburgh, Churchill Livingstone
2. Wright AL, *Diseases of the Nails* in ABC of Dermatology 2nd ed. p65 PK Buxton 1994: London, BMJ Publishing Group
3. Tortora GJ and Anagnostakos NP, *Principles of Anatomy and Physiology* 6th ed. p129 1990: New York, Harper Collins
4. Wright AL, *Diseases of the Nails* in ABC of Dermatology 2nd ed. p66 PK Buxton 1994: London, BMJ Publishing Group

Toe nails - Function and Management

Correct completion of this exercise will entitle you to 10 CPD credits. The answers are not necessarily given in the accompanying text and may need to be researched from text books, the Internet and scientific papers. Answers should be submitted on A4 paper and should be of sufficient length to demonstrate full understanding of the topic. Single word answers are not permissible. Try to answer in one or two short paragraphs, not more than a ¼ page.

1. Describe the anatomical relationships of the nail plate
2. Describe the extent of the germinal matrix
3. What factors determine the growth rate of the nail plate?
4. What is the effect of a period of non-growth?
5. What is the function and purpose of the nails?
6. What should be the extent of the trimmed normal nail?
7. How should the involuted nail be trimmed?
8. What is the effect of ground forces on the free edge of a nail on a retracted digit?
9. How would you trim the nail on an axially rotated digit?
10. Explain how HAV can generate onycholysis or onychocryptosis.

***Return this page with the administration fee (see Alliance webpage) and your answers to:
Alliance CPD Dept, Gateway, Forest Moor Road, Knaresborough HG5 8JY
10 CPD points will be awarded for successful completion.***

Failure to gain 40 CPD points in a practice year will leave you eligible for audit.

Name:Alliance Membership No:

Address:

.....

.....

Post Code: